

Morphological changes induced by mobile phone radiation in liver and pancreas in Wistar albino rats

Sultan Ayoub Meo¹, Muhammad Arif², Shahzad Rashied³, Sufia Husain⁴,
Muhammad M. Khan³, Abeer A. Al Masri¹, Muhammad S. Vohra³,
Adnan M. Usmani⁵, Ashraf Husain¹, Abdul M. Al-Drees¹

Departments of 1- Physiology, 2- Pharmacology, 3- Anatomy, 4- Pathology, 5- Strategic Center for Diabetes Research, College of Medicine, King Saud University, Riyadh, Kingdom of Saudi Arabia.

SUMMARY

Mobile phones are excessively used by the public in almost all the regions of the world. The aim of the present study was to determine the morphological changes induced by mobile phone radiation in the liver and pancreas in Wistar albino rats. A total of 40 male, Wistar albino rats were assigned for the study. The first group served as a control (n=8); the second group (Group B, n=16) was exposed to mobile phone radiation for 30 minutes, and the third group (Group C, n=16) was exposed to mobile phone radiation for 60 minutes daily for a total period of three months. Detailed morphological changes induced by mobile phone radiation were observed under light microscopy. Exposure to mobile phone radiation for 30 min/day caused inflammation of the liver in 18.75% of the animals (Group B). However, when the duration of exposure was increased to 60 min/day, we found inflammation in the liver in 43.75% and in pancreas in 31.25% of albino rats compared to their matched controls. It is concluded that long-term exposure to mobile phone radiation can cause inflammation in the liver and pancreas of albino rats. Based on this animal model study, such effects are also expected in humans, and it is therefore suggested that,

long term and/or unnecessary excessive use of mobile phones should be avoided.

Key words: Mobile phone radiation – Albino rats – Liver – Pancreas

INTRODUCTION

The emergence and evolution of mobile phones is one of the fastest in the history of innovation (Colonna, 2005). They are being used not only by adults but also by children. The number of mobile phone users is constantly increasing and the total number worldwide has surpassed 4.8 billion. This means that more than two-thirds of the world population is using this technology (Worldwide Mobile Phone users, 2009). Mobile phones and cell-phone towers generate Electromagnetic Field Radiation (EMFR) and have become a frequent source of contamination of the human environment by producing non-ionizing radiation (NIR) (Boris et al., 2010). This phenomenon has raised concerns about the possible hazards of the electromagnetic field radiation emitted by mobile phones on human health (Stuchley, 1988; Maier et al., 2000; Al-Khalaiwi and Meo, 2004; Meo and Drees, 2005; Karger, 2005; Kleinlogel et al.,

2008). The EMF radiation generated by mobile phones can inflict its results through both thermal and non-thermal effects (Derias et al., 2006; Acar et al., 2009). Despite the large number of studies published over a decade, it still remains uncertain that their use may lead to serious debilitating problems in the different body structures while placing the mobile phones or during its use Aitken et al., 2005; Christensen et al., 2005; Moulder et al., 2005; Shoemaker et al., 2005). Mobile phones are mainly placed in the front or side pockets (close to the heart, liver and pancreas) or hung with a waist belt (close to the reproductive organs). The extensive use of mobile phones has been followed by common public debate about possible adverse effects on human health. Thus, the present study was designed to investigate the effects of the Electromagnetic Field Radiation (EMFR) generated by mobile phones as regards the morphological findings in the livers and pancreata of albino rats.

MATERIALS AND METHODS

This study was conducted at the Department of Physiology, College of Medicine, King Saud University, Riyadh, Saudi Arabia.

Animal Model

A total of 40 male albino rats (Wistar strain), 2 months of age, weighing 150-160 g, with same genetic background were recruited for the experiment. The animals were housed in three cages in a similar environment and were fed with standard pelleted diet (Gold Mohar) and water ad-libitum. They were maintained under a controlled temperature of 22-24°C and had a 12-12-hour light-dark cycle (lights on 06:00-18:00 h) (Sokolovic et al., 2008). The experimental animal protocol was approved by the animal ethics board of the College of Medicine Research Centre, King Saud University, and experiments were performed according to the suggested guidelines.

Experimental Protocol

Wistar albino rats (n=40) were divided into three groups. Group A (n=8) served as a control and the remaining two groups, B and C (n=16 each), were exposed to EMF Radiation generated by a mobile phone at a specific time

of the day (during the lights-on period) for a total period of three months. Group B was exposed to mobile phone radiation for 0-30 minutes daily, and group C was exposed to mobile phone radiation for 31-60 minutes daily for three months. In this experiment, Global System for Mobile communications (GSM) handsets of mobile phones of the same brand and model were used. A mobile phone was placed inside the cage and a call was given with another mobile phone and it was also ensured that the mobile phone inside the cage was powered-on, and with call-accepting (answering) mode and the rats were in close proximity to the mobile phone (Sokolovic et al., 2008; Mailankot et al., 2009; Narayanan et al., 2009; Gul et al., 2009).

Histopathological examination

After completion of mobile phone radiation exposure for the total period of 3 months, the albino rats were sacrificed, the livers and pancreas were removed for histopathological examination. The organs were collected in 10% formalin before processing in a tissue processor (Vacuum infiltration processor, Tissue Tek VIP). The tissue samples were embedded in paraffin and 5 µm cross-sections were stained with hematoxylin-eosin. All slides were examined under a high-power microscope by an expert histopathologist.

Grading of the morphological findings: The composition of the inflammatory infiltration was determined based on the predominance of lymphocyte and histiocytes. All parameters were graded as negative =1; mild=1+; moderate= 2+; and severe =3+.

The findings were fed into a digital data sheet and the results were computed based on the percentage (%) of the morphological findings in liver and pancreas.

Statistical analyses

The morphological findings were entered into the computer. The percentage was obtained based on the number of animals. Fisher's Exact Chi-squared test was applied between the groups and the level of significance was considered at $p < 0.05$.

RESULTS

Figure 1 shows the morphological findings in the livers of Wistar albino rats that were exposed to mobile phone radiation. We found

inflammation in 3 albino rats (18.75%) that were exposed for 0-30 minutes daily and 7 (43.75%) in the animal that were exposed to 31-60 min/day for the total period of three months, as compared to their matched controls. The level of significance was ($p=0.52$) between the A versus B groups; ($p=0.053$) the A versus C groups; and ($p=0.25$) between the B versus C groups.

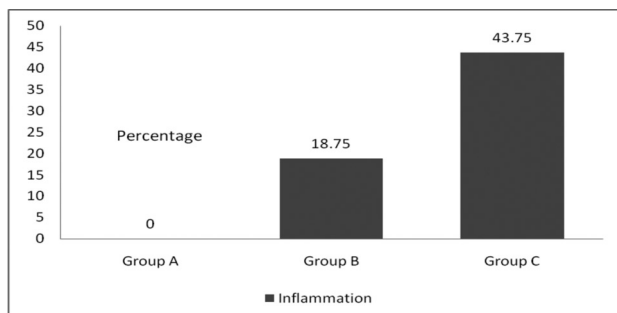


Figure 1. Effect of Electromagnetic Field Radiation generated by mobile phones on the liver of Wistar albino rats (N=40). Group A: Control (Not exposed to mobile phone radiation). Group B: Exposed to mobile phone radiation for 30 min daily for the total period of three months. Group C: Exposed to mobile phone radiation for 60 min daily for the total period of three months.

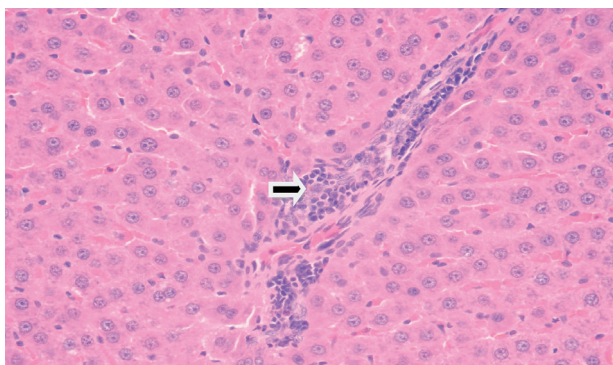


Figure 3. The Wistar albino rat liver (H+E stain, x 400) shows a mild inflammatory cell infiltrate of lymphocytes and histiocytes in the portal tract.

DISCUSSION

Mobile phone users are extensive worldwide. They are exposed to different frequencies in different countries and on different continents. Exposure to radiofrequency radiation depends upon the frequency of the cellular phone. The Electromagnetic Field Radiation generated by mobile phones may affect different organs and their functions via three mechanisms: an EMW-specific effect; a thermal molecular effect, or a combination of both (Dasdag et al., 1999). Animal model studies have shown that electromagnetic field radiation generated by mobile phones has a broad range of damaging effects on different organs/systems. As far as the present study is

We also observed inflammation of pancreatic cells in 5 (31.25%) albino rats that were exposed to 31-60 minutes daily over the total period of three months as compared to their matched controls, as shown in Fig. 2. The level of significance was ($p=0.13$) between A versus C, and ($p=0.04$) between the B versus C groups.

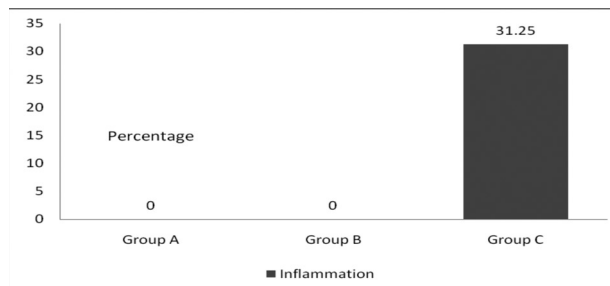


Figure 2. Effect of Electromagnetic Field Radiation generated by mobile phones on the pancreas of Wistar albino rats (N=40). Group A: Control (Not exposed to mobile phone radiation). Group B: Exposed to mobile phone radiation for 30 min daily for the total period of three months. Group C: Exposed to mobile phone radiation for 60 min daily for the total period of three months.

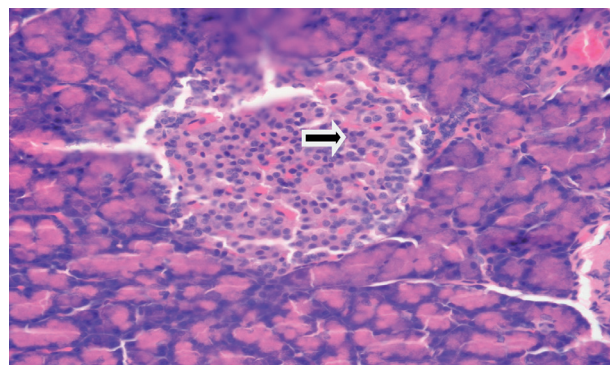


Figure 4. Wister albino rat pancreas (H+E Stain, x 400) shows a mild infiltration of lymphocytes in the islets of Langerhans (Insulinitis).

concerned, we found that long-term use of mobile phones can cause inflammation in livers and pancreatic cells of Wistar albino rats as compared to their matched control. Moreover, the liver inflammation increased with the duration of exposure to mobile phone radiation.

Boris et al. (2010) reported increased numbers of micronuclei and discrete perivenular fatty changes in the liver of EMFR-exposed rats. The serum activity of ALT and MDA concentrations was significantly higher in the liver tissues of exposed rats. Increases in ALT activity indicate cytotoxic effect of non-ionizing radiation on hepatocytes, inducing apoptosis and necrosis. An elevated oxyradical gen-

eration and subsequent cell membrane disruptions were reported to be the reasons for electromagnetic field-induced cell damage (Lahijani et al., 2009). Moreover, increases in lipid peroxidation as a direct indicator of hepatocyte injury under a long-term mobile phone radiation exposure together with increased ALT activity is also a marker of hepatocellular damage. Imaida et al. (1998) conducted a study on rats exposed to near-field EMR. They reported that the histopathological findings in the liver revealed changes, but the differences among the groups were not significant. Oral et al. (2006) observed that exposure to 900-MHz radiation emitted by mobile phones can cause endometrial apoptosis and oxidative stress in rats.

Lahijani et al. (2009) demonstrated the histopathological and ultra-structural changes in the livers of preincubated chicken embryos exposed to EMFs. Morphological observations indicated that EMFs would create hepatocytes with fibrotic bands, severe steatohepatitis, vacuolizations, swollen, crystallized mitochondria with degenerated cristae, dentate nuclei, degenerated hepatocytes, abnormal lipid accumulations, lipid droplets pushing hepatocyte nuclei to the corner of the cells, cellular infiltrations inside the sinusoid and around the central veins, and a disrupted reticulin plexus. An elevated oxyradical generation and subsequent cell membrane disruptions were the reasons for electromagnetic field-induced cell damage.

Kavindra and Kesari (2010) reported that microwaves generated from cellular phones affect biological systems by increasing free radicals, which may enhance lipid peroxidation, and by changing antioxidative activities, leading to oxidative damage. Moreover, they reported that catalase activity showed significant increase in livers as compared with controls. Their results suggested that regular use of mobile phones at domestic level could have negative impacts on enzymatic activity. (Kucer, 2008) demonstrated the ocular symptoms experienced during the use of mobile phones. They studied the different symptoms and found that mobile phones can cause inflammation in the eyes. Similarly, in the present study we found that long-term use of mobile phone can cause inflammation in the liver and pancreatic cells of albino rats as compared to their matched controls.

The interaction mechanisms of RF radiation emitted by mobile phones on liver tissue is not well understood, although there are some studies that, using 900 MHz RF radiation for 7 days to 3 months (30 min/day to 1 h/day), shows this association in relation to lipid peroxidation and free radical formation (Ozguner et al., 2005). It has also been demonstrated that RF radiation can induce oxidative damage by increasing antioxidant enzyme activities: ALT, MDA CAT and SOD (Ozguner et al., 2006). Akdag et al. (2008) reported that 2h/day (7days/week) exposure of 900 MHz radiation over a period of 10 months elicited an increase in MDA and TOS levels in the liver tissue of the exposed group as compared to sham group. Reactive oxygen species (ROS) induced by oxidative stress may be an important factor in tissue injury resulting from radiation (Jajte et al., 2002). Keeping in mind the results of previous studies, it can be ascertained that long term use of mobile phones can cause several effects, including inflammation of the liver and pancreas. Since the literature is lacking in descriptions of any association of mobile phones and their effects on pancreatic cells, in the present study we were prompted to study the morphological findings in both liver and pancreatic cells of albino rats.

Conclusion: Long-term exposure to mobile phone radiation can cause inflammation in the liver and pancreatic cells of Albino rats. Based on this animal model study, such effects are also expected in humans, and we therefore suggest that long term and/or excessive use of mobile phones should be avoided.

ACKNOWLEDGEMENTS

This work was supported by grant 05-493, College of Medicine, Research Centre (CMRC), King Saud University, Riyadh KSA. We would like to express our gratitude to the Dean's Office of Scientific Research, KSU and Director CMRC for providing funding. We also thank the staff of the Animal House, College of Medicine, King Saud University for cooperation.

Proprietary interest: No conflict of interest with any institution / organization.

Institutional approval: Institutional approval was obtained in compliance with regulation of our institution and generally accepted guidelines governing such work.

REFERENCES

- ACAR GO, YENER HM, SAVRUN FK, KALKAN T, BAYRAK I, ENVER O (2009). Thermal effects of mobile phones on facial nerves and surrounding soft tissue. *Laryngoscope*, 119: 559-562.
- AITKEN RJ, BENNETTS LE, SAWYER D, WIKLENDT AM, KING BV (2005). Impact of radio frequency electromagnetic radiation on DNA integrity in the male germline. *Int J Androl*, 28: 171-179.
- AKDAG MZ, BILGIN MH, DASDAG S, TUMER C (2007). Alteration of nitric oxide production in rats exposed to a prolonged, extremely low-frequency magnetic field. *Electromagn Biol Med*, 26: 99-106.
- AL-KHALAIWI T, MEO SA (2004). Association of mobile phone radiation with fatigue, headache, dizziness, tension and sleep disturbance in Saudi population. *Saudi Med J*, 25: 732-736.
- BORIS Đ, DUŠAN S, DEJAN K, DEJAN P, JOVICA J, MARJAN M (2010). Biochemical and histopathological effects of mobile phone exposure on rat hepatocytes and brain. *Acta Medica Medianae*, 49: 37-42.
- CHRISTENSEN HC, SCHUZ J, KOSTELJANETZ M, POULSEN HS, BOICE JD JR, MCLAUGHLIN JK (2005). Cellular telephones and risk for brain tumors: a population-based incident case-control study. *Neurology*, 64: 1189-1195.
- COLONNA A (2005). Cellular phones and cancer: current status. *Bull Cancer*, 92: 637-643.
- DASDAG S, KETANI MA, AKDAG Z, ERSAY AR, SARI I, DEMIRTAS OC (1999). Whole-body microwave exposure emitted by cellular phones and testicular function of rats. *Urol Res*, 27: 219.
- DERIAS EM, STEFANIS P, DRAKELEY A, GAZVANI R, LEWIS-JONES DI (2006). Growing concern over the safety of using mobile phones and male fertility. *Arch Androl*, 52: 9-14.
- GUL A, CELEBI H, UĞRAŞ S (2009). The effects of microwave emitted by cellular phones on ovarian follicles in rats. *Arch Gynecol Obstet*, 280: 729-733.
- IMAIDA K, TAKI M, YAMAGUCHI T, ITO T, WATANABI S-I, WAKE K, AIMOTO A, JAJTE J, GRZEGORCZYK J, ZMYSLONY M, RAJKOWSKA E (2002). Effect of 7 mT static magnetic field and iron ions on rat lymphocytes: apoptosis, necrosis and free radical processes. *Bioelectrochemistry*, 57: 107-111.
- KARGER CP (2005). Mobile phones and health: Literature overview. *Z Med Phys*, 15: 73-85.
- KAVINDRA K, KESARI JB (2010). Whole body 900 MHz radiation exposure effect on enzyme activity in male wistar rats. Available at: <http://wifischools.org.uk/resources/Kesari+and+Behari+.pdf> (cited date: July 15, 2010).
- KLEINLOGEL H, DIERKS T, KOENIG T, LEHMANN H, MINDER A, BERZ R (2008). Effects of weak mobile phone-electromagnetic fields (GSM, UMTS) on well-being and resting EEG. *Bioelectromagnetics*, 29: 479-487.
- KÜÇER N (2008). Some ocular symptoms experienced by users of mobile phones. *Electromagn Biol Med*, 27: 205-209.
- LAHIJANI MS, TEHRANI DM, SABOURI E (2009). Histopathological and ultrastructural studies on the effects of electromagnetic fields on the liver of preincubated white Leghorn chicken embryo. *Electromagn Biol Med*, 28: 391-413.
- MAIER M, COLIN B, KOIVISTO M (2000). The health hazards of mobile phones. *Brit Med J*, 320: 1288-1289.
- MAILANKOT M, KUNNATH AP, JAYALEKSHMI H, KODURU B, VALSALAN R (2009). Radio frequency electromagnetic radiation (RF-EMR) from GSM (0.9/1.8GHz) mobile phones induces oxidative stress and reduces sperm motility in rats. *Clinics (Sao Paulo)*, 64: 561-565.
- MEO SA, AL DREES AM (2005). Mobile phone related hazards and subjective hearing and vision symptoms in the Saudi Population. *Intl J Occupational Med Environm Health*, 18: 53-57.
- MOULDER JE, FOSTER KR, ERDREICH LS, MCNAMEE JP (2005). Mobile phones, mobile phone base station and cancer: a review. *Int J Radiat Biol*, 81: 189-203.
- NARAYANAN SN, KUMAR RS, POTU BK, SATHEESHA N, MAILANKOT M (2009). Spatial memory performance of Wistar rats exposed to mobile phone. *Clinics*, 64: 231-234.
- ORAL B, GUNAY M, OZGUNER F, KARAHAN N, MUNGAN T, COMLEKCI S, CESUR G (2006). Endometrial apoptosis induced by a 900-MHz mobile phone: Preventive effects of vitamins E and C. *Advances in Therapy*, 23: 957-973.
- OZGUNER F, OKTEM F, AYATA A, KOYU A, YILMAZ HR (2005). Novel antioxidant agent caffeic acid phenethyl ester prevents long-term mobile phone exposure-induced renal impairment in rat. Prognostic value of malondialdehyde, N-acetyl-beta-D-glucosaminidase and nitric oxide determination. *Mol Cell Biochem*, 277: 73-80.
- OZGUNER F, BARDAK Y, COMLEKCI S (2006). Protective effects of melatonin and caffeic acid phenethyl ester against retinal oxidative stress in long-term use of mobile phone: a comparative study. *Mol Cell Biochem*, 282: 83-88.
- SHOEMAKER MJ, SWERDLOW AJ, AHLBOM A, AUVINEN A, BLAASAAS KG, CARDIS E (2005). Mobile phone use and risk of acoustic neuroma: results of the interphone case-control study in five North European countries. *Br J Cancer*, 93: 842-848.
- SOKOLOVIC D, DJINDJIC B, NIKOLIC J, BJELAKOVIC G, PAVLOVIC D, KOCIC G (2008). Melatonin reduced stress induced by chronic exposure, of microwave radiation from mobile phone. *J Radiation Research*, 49: 579-586.
- STUCHLEY MA (1988). Biological effects of radiofrequency fields. In: Repacholi MH (ed). *Non-Ionizing Radiations: Physical characterization, Biological effects and Health Hazard Assessment*. Proceedings for the International Non-Ionizing Radiation Workshop, Melbourne, pp 197-217.
- WORLDWIDE MOBILE PHONE USERS (2009). More than four billion mobile phone users worldwide (Accessed dated Nov 24, 2009). Available at <http://www.infobalt.lt/main.php?&a=0&i=7983>.