

WAS RIFE RIGHT? A 32-YEAR-OLD INFECTION CURED IN 2 HOURS BY A PLASMA TUBE RADIATION.

**ANDRE BELLOSSI¹, GERARD DUBOST², JAMES BARE³,
JOSE LUIS BARDASANO RUBIO⁴**

1 MD – PROFESSOR OF MEDICAL BIOPHYSICS – FRANCE - andre.bellossi@free.fr

2 EMERITUS PROFESSOR OF PHYSICS UNIVERSITY OF RENNES 1– FRANCE-
dubost.gerard@wanadoo.fr

3 DC – ALBUQUERQUE – NM – US jbare@plasmasonics.com

4 MD – PROFESSOR OF ANATOMOPATHOLOGY – ALCALA DE HENARES- SPAIN

Abstract.

We present the case of a dramatic treatment response to a diagnosis conundrum which, after 32 years and more than 60 surgical operations, was cured in less than 3 hours by the radiation of a plasma tube.

In 1973 Mrs R. was a 27-year-old woman when the troubles began with a violent pain in her upper maxilla. From this beginning, there were recurrent severe attacks of her state of health followed by multiple surgical operations. Continued failure of medical treatments led to the consideration of successive hypotheses: an infectious rheumatism, then a collagenosis and at the end a diagnosis of Wegener's granulomatosis led to the prescription of immunosuppressive drugs. In fact her problem was a matter of an osteitis with two unfavourable features: an undiscovered bacterial source and a total ineffectiveness of medical treatment.

In February 2005 the situation had become unbearable and a compassionate treatment using plasma tube radiation, similar to that used by Rife in the thirties, was decided upon. The result was almost immediate and spectacular. By the evening following treatment, her body temperature had normalized at 37°C, and 4 days later the patient spat out an abscess from the left side of her throat.

The explanation for treatment effectiveness resides in the half-resonance frequency of irradiated bacterial DNA. With hindsight of 5 years there has been no infectious relapse.

Introduction.

Mrs R. was a 27-year-old woman on April 1973 when she was affected by a violent pain in the upper left jaw at the canine level. The canine was extracted and the jawbone cleaned. On December 1974 the pain with fever reappeared leading to the surgical curetting of an osteitic jawbone, this time on the right side. However on January 1975 an attack of the general state of health with severe pain, fever, shiver, sweat, asthenia, generalized arthralgias, myalgias, loss of weight led to a hospitalization. The diagnosis of infectious rheumatism due to streptococcus was envisaged but a two-month treatment gave no improvement. Until May 1976 a combination of antibiotics, anti-inflammatory drugs, corticoids, produced no effect. Then a collagenosis was considered and the patient received, among other drugs, as immunosuppressive treatment, aziathoprine and corticoids. Six months later the situation deteriorated with a significant worsening of her general state of health. This was marked by exhaustion, unbearable myalgias and arthralgias and a brutal resumption of jawbones pains. Several surgical operations followed on 22nd and 30th of January, 10th and 21st of February and June 1977. An anatomopathological examination suggested a possible Wegener's granulomatosis. This hypothesis led to the addition of a second immunosuppressor, cyclophosphamide, to the treatment. Surgical operations continued in November 1977, the 3rd and the 23rd of May 1978, in November 1978. Then, against medical advices, Mrs R. stopped all immunosuppressive drugs and looked for other treatments.

One of us (AB) met Mrs R. in March 1979. Between 1973 and 1979 she endured 14 surgical operations on the upper jawbone and suffered from about 8 non-periodic painful crises each year. Each crisis was always of the same type: they began suddenly with fever (about 38°C), sweat, articular pain in the large joints, pain in the spinal joints, pain in tendons and muscles, weight increase and very intense inflammatory biological modifications. Each attack lasted from 4 to 8 weeks and ended quickly within one day. To have a better idea of the real ailment we asked the help of a diagnosis computer assistance. The device answered osteitis. Immunochemical analysis was in favour of a bacterial infection with exhaustion of the immune system. The hypothesis of a repeated infection from a hidden bacterial source looked plausible. As a matter of fact a throat

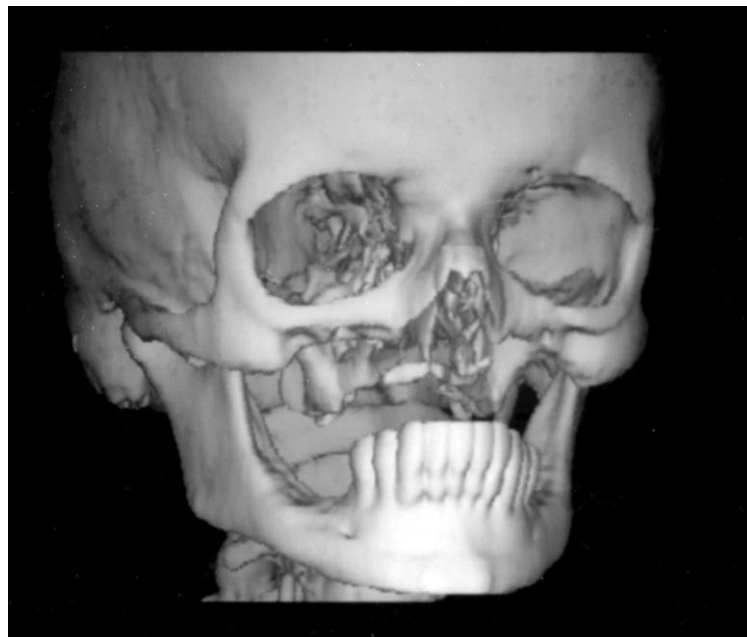
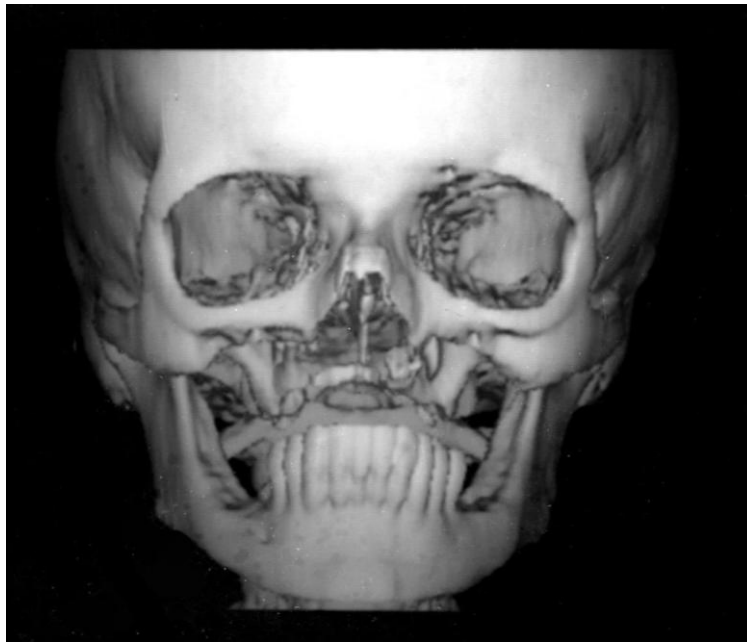
.

A.BELLOSI, G.DUBOST, J.BARE, JL BARDASANO RUBIO.

infection on December 1985 identified *Streptococcus faecalis*, *Escherichia coli*, *Hafnia* and Yeasts. Unfortunately the bacterial source could not be discovered and, despite different types of treatment, each feverish painful crisis succeeded another eventually leading to surgical operations. A treatment with pulsed magnetic fields brought a temporary lull between 1991 and 1993 but the problem came back on January 1994. On January 1996, in a sample from a surgical operation, *Escherichia coli*, *Streptococcus agalactiae*, *Staphylococcus aureus* and Yeasts were identified demonstrating the inefficiency of the antibacterial drugs. On the 3rd of June 1998 a scanner showed the almost complete disappearance of the bone palate, of the jaw sinus bottom wall, of the right orbital floor.

Here are two 3D-reconstruction photos 1 and 2 .


PHOTOS 1, 2.



BACTERIAL INFECTION AND PLASMA TUBE RADIATION

That way of life continued and by February 2005 she had supported more than 60 surgical operations in the jawbone. By February 2005, in addition to the pain, Mrs R. put up with a constant febrile state of several months duration, with a body temperature around 38°C, up to 39°C.

PHOTO 3.



In the thirties, in the USA, Royal Raymond Rife reported the killing of bacteria by means of the radiation of a plasma tube. So, it was decided to try a compassionate treatment using Bare/Rife system (photo 3). The radiation was produced by a plasma tube filled with argon (80%) and neon (20%) gas at a pressure of 50 mm of mercury. The tube lighting was accomplished using a highly (>300 %) over modulated, AM type, radiofrequency electronic discharge. By using the square wave generated frequencies for modulation, along with overmodulation of the carrier wave, a pulsed emission was achieved. Treatment was done successively with the following modulation low frequencies : 723 to 730 Hz (*Staphylococcus aureus*), 877 to 884 Hz (*Streptococcus pyogenes*), 749 to 755 Hz (*Proteus vulgaris*), 756 to 761 Hz (*Enterococcus faecalis*), 764 to 771 Hz (*Proteus mirabilis*), 800 to 807 Hz (*Escherichia coli*).

The session took place on the 4th of February 2005 at the rate of 3 minutes per frequency (135 minutes for the set) and ended at 16 o'clock. At night the fever had disappeared with a body temperature at 37°C. Four days later, suddenly, Mrs R. spat out a stinking, putty-like substance coming from the left side of her throat. Laboratory analysis revealed a pile of polymorphous bacteria mixed with fungus filaments. Four months later,

A.BELLOSSI, G.DUBOST, J.BARE, JL BARDASANO RUBIO

while undergoing yet another surgery, the surgeon found a grey, lava-like bone lesion, well separated from the healthy bone. Since then no infectious relapse has taken place.

Since then the theoretical explanation of bacterial destruction by electromagnetic fields has been given (1). It is due to half-wave resonance of irradiated bacteria DNA, half-wave resonance being linked to the water dipoles associated to DNA. The half-wave resonance frequencies depend on the base-pair number within the DNA of the micro organism, and so a unique treatment frequency is a characteristic of a particular species or strain of bacterium. Half-resonance frequencies for the most part of bacteria range from 4 to 8 GHz, values given by the cylindrical plasma antenna, are obtained from the pulsed modulation frequency of the 27.12 MHz carrier.

Recently our theoretical explanation of bacterial destruction given in (1) has been confirmed by means of a wide bandwidth horn tied with a spectrum analyser used to measure the plasma antenna radiation in the range from 1.5 to 18 GHz (see photo 4). We measured a significant power density at frequencies about 3.05 GHz for a modulation frequency equal to 1.4 KHZ, and at frequencies about 6.1 GHz for a modulation frequency equal to 0.7 KHZ.

So the DNA half-wave resonance hypothesis of bacteria irradiated by frequencies between 4 and 8 GHz (1) has been justified by recent experiments.

Mrs R., is now relieved of infection and her 8 times a year crises, but a pain problem, due to nerve damage from surgical after-effects, remains.

Acknowledgement

The authors thank Mr Bruno Dewavrin, Application Engineer AGILENT TECHNOLOGIES FRANCE, who has given help to measure with efficiency and cleverly the plasma antenna radiated fields. .

Summary.

A hidden bacterial source inaccessible to antibacterial drugs led to a diagnosis conundrum for 32 years. The patient endured more than 32 surgical operations on the upper jawbone and an almost constant pain. The recovery was obtained in less than 3 hours by means of the radiation of a plasma tube.

References.

(1). Half-wave resonance of bacteria DNA irradiated from 4 to 8 GHz. G. Dubost, A. Bellossi BioEM 2009 Abstract Collection P170 : 583-585.

PHOTO 4.



